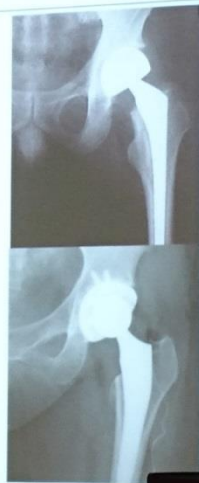

人工骨頭置換術：BHA

大腿骨側のみ



人工股関節全置換術：THA

大腿骨と骨盤両方



ALHORA 407479-2

ParaBoard US 1500





椎体間固定

椎間板、軟骨終板を切除

椎体

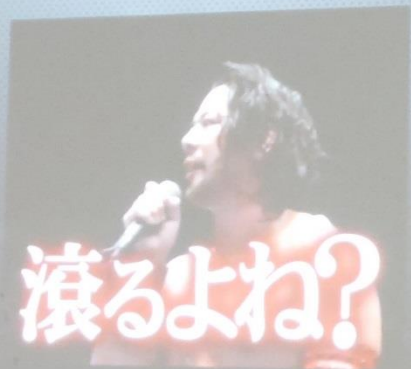
骨移植、ケージの挿入



The slide displays two X-ray images of a vertebra. The left image shows the vertebra with a red circle highlighting the intervertebral disc space. The right image shows the vertebra after the disc and endplates have been removed, with a cage and bone graft inserted. A diagram below shows a blue circle representing the vertebra with a red '1' and a yellow arrow pointing to the cage and bone graft.

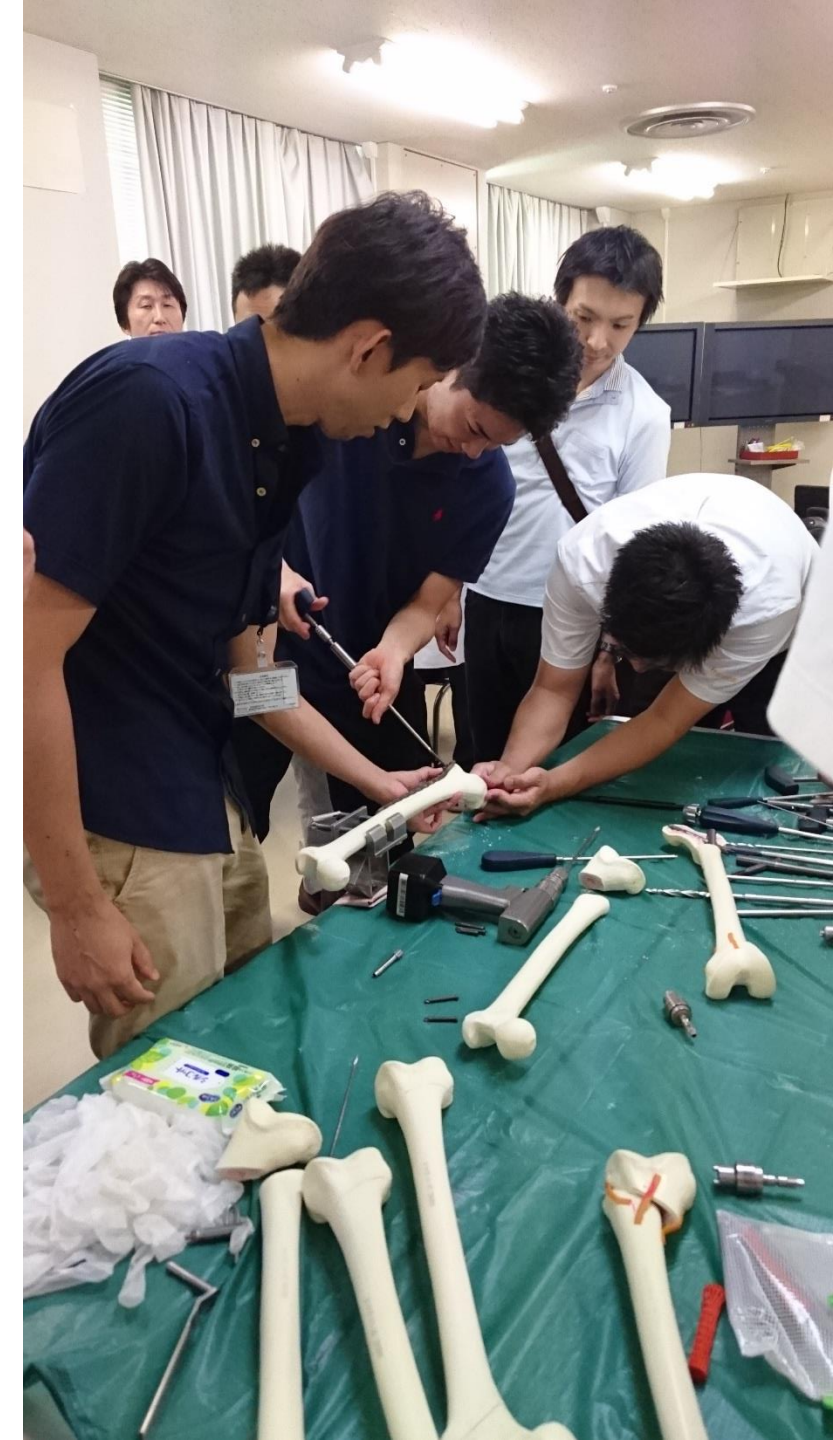
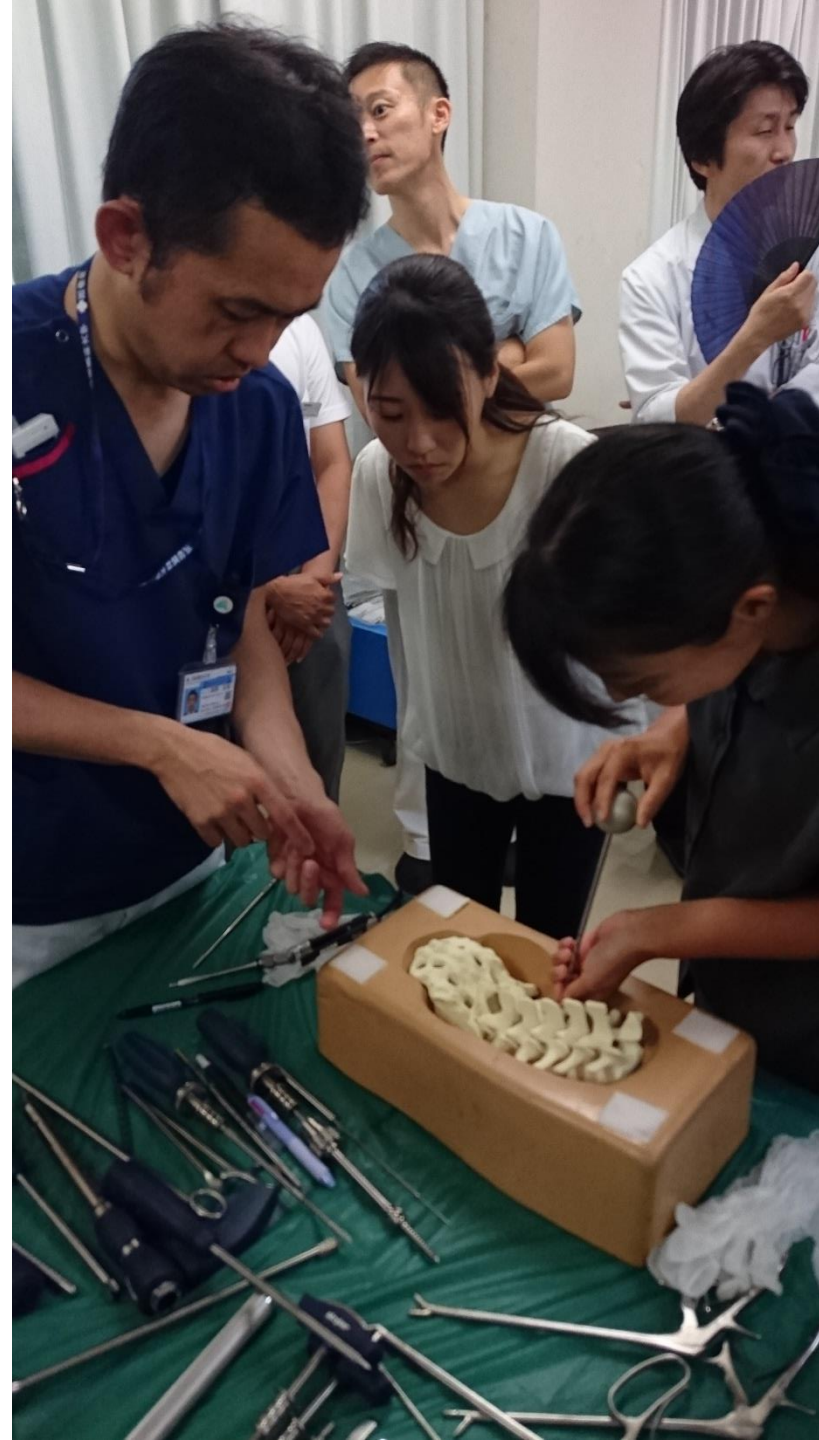


でも外傷（骨）を愛し骨に愛される者は



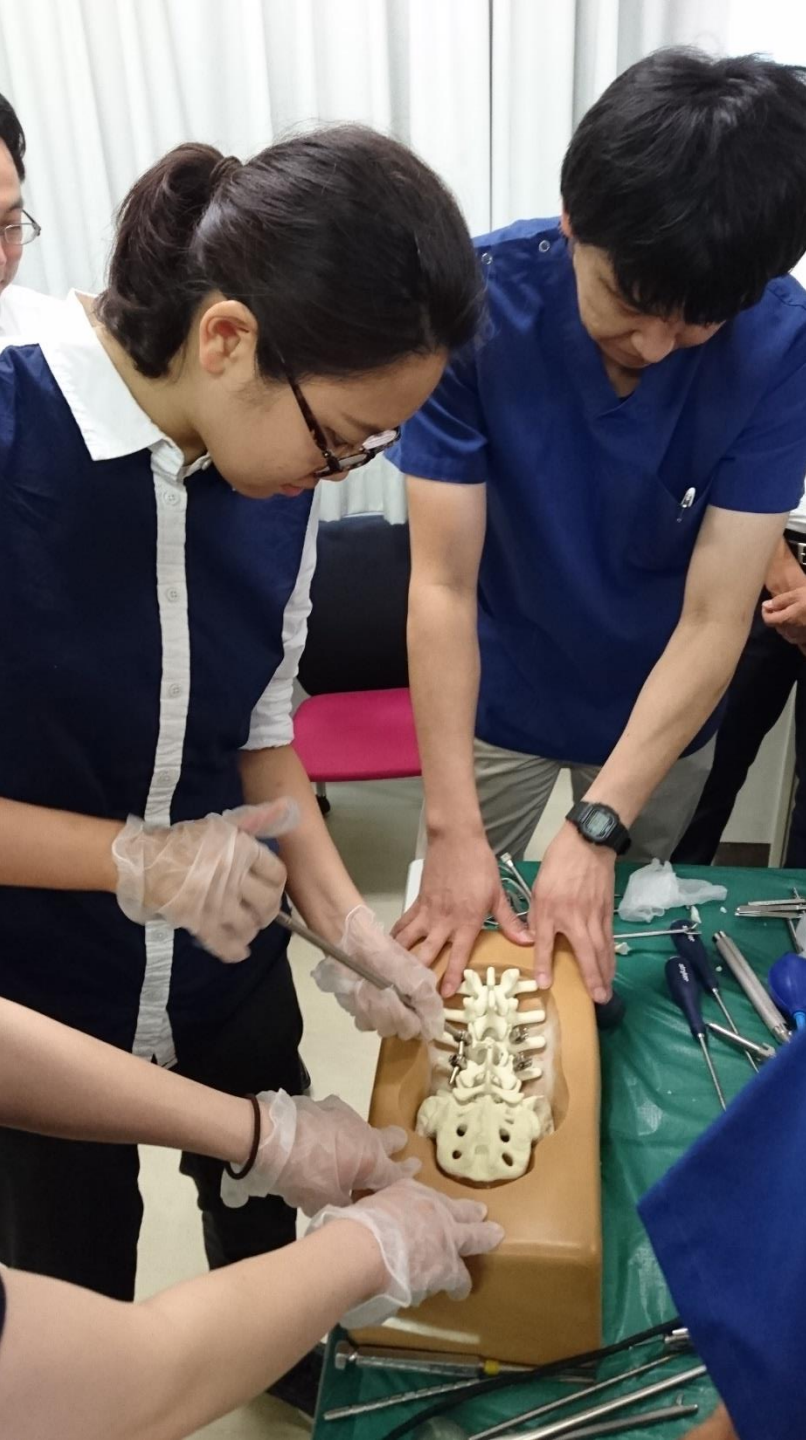SI-HOBA
2019.11.17













集会所を利用される方へ
集会所で飲食された場合、ゴミは
必ず持ち帰ること。
部屋内や廊下のゴミ箱に捨てな
いでください。



